

Carotid intima-media thickness by B-mode ultrasound as surrogate of coronary atherosclerosis: correlation with quantitative coronary angiography and coronary intravascular ultrasound findings

Mauro Amato¹, Piero Montorsi^{1,2}, Alessio Ravani¹, Elisa Oldani¹, Stefano Galli^{1,2}, Paolo M. Ravagnani^{1,2}, Elena Tremoli^{1,3}, and Damiano Baldassarre^{1,3*}

¹Centro Cardiologico Monzino, IRCCS, Via Parea 4, 20138 Milan, Italy; ²Institute of Cardiology, School of Medicine, University of Milan, Milan, Italy; and ³Department of Pharmacological Sciences, University of Milan, Via Balzaretti 9, 20133 Milan, Italy

Received 6 February 2007; revised 4 May 2007; accepted 22 May 2007; online publish-ahead-of-print 27 June 2007

See page 2049 for the editorial comment on this article (doi:10.1093/eurheartj/ehm320)

KEYWORDS

Angiography;
IVUS;
Ultrasound;
Carotid;
Coronary

Aims Although well supported by postmortem studies, the reliability of carotid atherosclerosis as surrogate marker of coronary atherosclerosis has been put in doubt by *in vivo* studies showing a poor correlation between carotid intima-media thickness (IMT) detected by external carotid ultrasound (ECU) and coronary stenosis assessed by quantitative coronary angiography (QCA). In the present study, we have investigated whether a stronger *in vivo* correlation between the two arteries can be obtained by using homogeneous variables such as carotid and coronary IMT, detected by ECU and intravascular ultrasound (IVUS), respectively.

Methods and results ECU, QCA, and IVUS measurements were made in 48 patients. Carotid IMT was correlated with both angiographic and IVUS findings. A significant but weak correlation was observed between ECU and QCA variables ($r \approx 0.35$, $P < 0.05$); the correlation between ECU and IVUS measurements of IMT was higher, with correlation coefficients ranging from 0.49 to 0.55. In patients with a QCA diagnosis of normal/intermediate coronary atherosclerosis, the presence of a carotid- $IMT_{mean} > 1$ mm was associated with an 18-fold increase in risk of having a positive IVUS test (OR = 17.99, 95% CI 1.83–177.14, $P = 0.013$) and with a seven-fold increased risk of having a significant IVUS coronary stenosis (OR = 7.4, 95% CI 1.27–44.0, $P = 0.028$).

Conclusion Carotid atherosclerosis correlates better with coronary atherosclerosis when both circulations are investigated by the same technique (ultrasound) using the same parameter (IMT). This supports the concept that carotid IMT is a good surrogate marker of coronary atherosclerosis.

Introduction

High resolution B-mode ultrasound is a non-invasive technique widely used to assess atherosclerosis in superficial arteries. It allows the accurate measurement of the distance between blood-intima and media-adventitia interfaces of the carotid wall, which is defined as carotid intima-media thickness (IMT).¹ Several authors have suggested that carotid IMT is a marker of atherosclerosis in other vascular beds.^{2–4} Indeed, an increased carotid IMT has been associated with a number of atherosclerosis risk factors,^{5–7} with the prevalence and extent of coronary artery disease (CAD)^{8,9} and with the incidence of new coronary and cerebral events.^{4,10} In view of these relationships, carotid IMT has been proposed as a surrogate endpoint to be

used in clinical trials as an alternative to coronary atherosclerosis.¹¹

In spite of the widespread use of carotid IMT as a surrogate for CAD, validation studies evaluating the correlation between carotid IMT measured by external carotid ultrasound (ECU) and CAD measured by quantitative coronary angiography (QCA) showed a relatively poor correlation ($r < 0.36$ on average).^{12–20} This finding has cast doubt on the reliability of carotid atherosclerosis as a surrogate marker of coronary atherosclerosis. Postmortem studies, however, have shown a far greater degree of correlation between the two arterial districts,^{21–24} which suggests that the poor correlation observed in ECU vs. QCA studies may be due more to technical issues than to differential effects of the traditional vascular risk factors on the carotid and coronary tissues.

Intravascular ultrasound (IVUS) is a unique imaging modality for the direct examination of vessel dimensions

* Corresponding author. Tel: +39 02 58002253; fax: +39 02 58002623.
E-mail address: damiano.baldassarre@unimi.it

and arterial wall characteristics in live subjects.^{25–28} Like ECU, IVUS measures, in addition to lumen diameter, plaque area and any thickening of arterial walls. Carotid and coronary arterial districts can then be compared using the same arterial wall parameter, namely the IMT. Unfortunately, in the only study so far published addressing the relationship between IVUS-detected coronary atherosclerosis and carotid ultrasonic measurements, carotid IMT was correlated with coronary percent plaque area, and the correlation between IMT in the two vascular districts was not investigated.²⁹

We therefore investigated whether correlations stronger than those observed in QCA studies and closer to those observed in postmortem studies could be obtained by using the homogeneous variable IMT. We also evaluated whether carotid IMT would identify subjects with IVUS-detected evidence of coronary atherosclerosis among patients with a QCA diagnosis of no or intermediate coronary lesions.

Methods

Study population

Forty-eight consecutive patients who had undergone coronary angiography and who required IVUS examination were included in the study. Indications for coronary angiography were suspected or proven CAD by clinical and non-invasive tests in 38, scheduled valve replacement in seven and major vascular surgery in three patients. Indications for IVUS were the need for precise assessment of intermediate degree coronary stenosis as detected by on-line QCA analysis or unclear coronary anatomy. Coronary angiography was performed by the standard Judkins technique. Each patient underwent ECU evaluation within a median of 2 days (inter-quartile range = 1–3 days) after the angiography. Only patients with one-vessel disease were included in the study, because (i) patients requiring multi-vessel IVUS evaluation are rare and (ii) an IVUS procedure in unambiguous vessels performed for research reasons alone is not ethically acceptable. Patients with a history of previous percutaneous or surgical myocardial and/or carotid revascularization were excluded. Written informed consent was obtained from all patients, and the Institution's Ethics Committee approved the study.

External carotid ultrasound

Carotid ultrasound scans were carried out by a single trained sonographer (M.A.) unaware of QCA and IVUS results using an Acuson Aspen system, equipped with a 7–10 MHz linear array transducer. Ultrasonic scans were recorded on sVHS videotapes.

The ultrasonic protocol requires the visualization of the near and far wall of the right and left common carotid, internal carotid artery, and bifurcation in three different projections: anterior, lateral, and posterior, for a total of approximately 30 carotid segments per patient. The ultrasonic variables used in the statistical analyses were the mean IMT of common carotids (CC-IMT_{mean}), bifurcations (Bif-IMT_{mean}), internal carotid arteries (ICA-IMT_{mean}), and of the whole carotid tree (Carotid-IMT_{mean}). The highest IMT value was defined as 'maximum IMT' (Carotid-IMT_{max}). The single reader (EO) of these measurements was unaware of QCA and IVUS results. Measurements were made with a specific software (M'ATH)³⁰ that allows the semiautomatic measurement of the distances between the two echogenic lines defining the boundaries of the intima plus media.

Quantitative coronary angiography

On-line QCA analysis was performed using ARTREK Quantum IC (Image Comm System, Sunnyvale, CA, USA) by a trained observer blind to ECU results. The outer diameter of the contrast-filled

catheter was used for calibration. Coronary lesions were analysed in several projections and the reference vessel diameter, minimal lumen diameter (MLD), and per cent diameter stenosis (%DS) were measured in the 'most severe' angiographic view. QCA findings were also expressed in terms of Gensini's score,³¹ which is an index of coronary atherosclerotic burden.

Coronary intravascular ultrasound

IVUS imaging used was a 30 MHz mechanical ultrasound transducer rotating at 1800 r.p.m. The patient received nitrate (200 µg i.c.) and heparin (2500 U i.v.) prior to IVUS investigation.

Images were acquired using a validated³² automated pullback device withdrawing automatically at 0.5 mm/s within a 3.2 F short monorail imaging catheter (CardioVascular Imaging System, Inc., Sunnyvale, CA, USA). Transducer was positioned within the target vessel (in which QCA showed a %DS > 40%) distal to the culprit lesion and progressively withdrawn for the entire length of the vessel. Anatomical landmarks (collateral vessels) were used to identify by IVUS the site where the culprit lesion was detected by QCA. In patients without a clearly detectable QCA lesion (%DS < 40%), but with unclear coronary anatomy, IVUS examination was performed in the left anterior descending artery. Images were recorded on sVHS videotapes.

IVUS measurements were made according to the standards of American College of Cardiology and European Society of Cardiology, as previously described.³³ The first distal image of the IVUS pullback was selected as the beginning point, and the image was then measured at 2 s intervals, generating a series of cross-sectional images 1 mm apart.

For each cross-sectional image, external elastic membrane cross-sectional area (EEM-CSA) and the lumen CSA (L-CSA) were determined as previously reported.³⁴

Because calcium acoustic shadowing in the target lesion makes measurement of EEM-CSA difficult, coronary segments with >90° of circumferential calcium or 1.0 mm of axial calcium were excluded. The circumferential arc of calcium was measured using a protractor centred on the lumen; the axial length of calcium was measured by counting the number of seconds of videotape on which lesion calcium was present (2 s of videotape = 1 mm axial arterial length).³³ When acoustic shadowing involved a relatively small arc (<90°), planimetry of the circumference was performed by extrapolation from the closest identifiable EEM borders.

Coronary IMT was calculated as the radius of a circle having an area equivalent to L-CSA minus the radius of a circle having an area equivalent to EEM-CSA as follows:

$$\text{Coronary-IMT} = [\sqrt{(\text{EEM-CSA} \times \pi^{-1})}] - [\sqrt{(\text{L-CSA} \times \pi^{-1})}].$$

The average value of the coronary-IMT measurements, performed in the entire length of investigated vessel, was considered as mean coronary-IMT (Coronary-IMT_{mean}). Coronary-IMT_{max} was defined as the highest cross-sectional Coronary-IMT value.

Total atheroma volume (TAV), in the last 10 mm from the aorto-ostial junction, was calculated using Simpson's rule as mean atheroma area (L-CSA minus EEM-CSA) multiplied by pullback length in millimetres.³⁵

The per cent atheroma volume (PAV) of the same coronary segment was computed as:

$$\frac{\sum \text{atheroma area}}{\sum \text{EEM-CSA}} \times 100.$$

The IVUS coronary volumetric and IMT variables were measured twice, 1 week apart, by a single trained reader (A.R.) unaware of ECU and QCA results. When there were differences between the two independent measurements greater than the coefficient of repeatability (Bland-Altman procedure),³⁶ a third measurement was made and the mean was used in the analyses. In our catheterization laboratory, intra-observer and inter-observer variability of

L-CSA and EEM-CSA measurements in CAD patients is 2.0 ± 2.2 , 3.0 ± 2.0 and 1.7 ± 1.6 and $2.5 \pm 1.8\%$, respectively.³⁴

Statistical methods

The correlations between ECU, QCA, and IVUS variables were evaluated by Spearman's rank correlation analysis. Age-adjusted partial correlation was performed after arcsin transformation of variables expressed in per cent (Coronary-%DS and PAV) and after log transformation of continuous variables (Coronary and carotid IMTs, Gensini's score, and TAV). The potential of ECU and QCA variables to identify patients with a positive IVUS test [IVUS⁽⁺⁾] was analysed in terms of sensitivity, specificity, and predictive values and through the receiver operating characteristic (ROC) curves or by logistic regression analysis. Statistical analyses used SPSS 13.0 for Windows. Data are presented as mean \pm SD or median and range when appropriate. *P*-values less than 0.05 were considered significant.

Results

Clinical characteristics of the study patient population are shown in Table 1.

Table 1 Patients' characteristics (*n* = 48)

Age (years)	61 \pm 8
Sex (M/F)	36/12
Body mass index (kg/m ²)	25.8 \pm 3.2
Risk factor prevalence	
Hypertension (%)	24 (50%)
Hypercholesterolemia (%)	35 (72.9%)
Currently smokers (%)	12 (25%)
Family history of CAD	30 (62.5%)
Diabetes (types 1 and 2)	0 (–)
Obesity (BMI > 30 kg/m ²)	4 (8.3)
Extra-cardiac arterial involvement	
Cerebrovascular disease (%)	1 (2.1)
Peripheral arterial disease (%)	3 (6.3)
Coronary artery analysed	
Left main trunk (%)	4.2
Left anterior descending artery (%)	79.2
Left circumflex artery (%)	12.5
Right coronary artery (%)	4.1
QCA parameters	
Coronary-%DS	50.8 \pm 30
Gensini's score	14.2 \pm 20.2
Coronary IVUS	
Minimal lumen area (mm ²)	2.83 \pm 1.33
Area stenosis (%)	65.2 \pm 12
Coronary-IMT _{mean} (mm)	0.42 \pm 0.15
Coronary-IMT _{max} (mm)	0.75 \pm 0.25
TAV (mm ³)	44.5 \pm 20
PAV (%)	40.1 \pm 12.3
ECU data	
CC-IMT _{mean} (mm)	1.06 \pm 0.25
Bif-IMT _{mean} (mm)	1.38 \pm 0.45
ICA-IMT _{mean} (mm)	1.12 \pm 0.48
Carotid-IMT _{mean} (mm)	1.19 \pm 0.33
Carotid-IMT _{max} (mm)	2.13 \pm 0.95

CAD, coronary artery disease; %DS, per cent diameter stenosis; Coronary-IMT_{mean}, average of 10 cross-sectional coronary-IMT measurements; Coronary-IMT_{max}, highest cross-sectional Coronary-IMT value; IMT, intima-media thickness; TAV, total atheroma volume; PAV, per cent atheroma volume; CC = Common Carotids; Bif = Bifurcations; ICA = Internal Carotid Arteries; Carotid-IMT_{mean}, average IMT value of the whole carotid tree; Carotid-IMT_{max}, highest IMT value of the whole carotid tree.

Men constituted 75% of the patients recruited, with age range 41–74 years. None of the patients had diabetes mellitus. The vessel involved was the left anterior descending artery in almost 80% of cases. Coronary-%DS_{max} was >70% in 13 (27%) patients, between 40 and 70% in 19 (40%), and <40% in 16 (33%) patients.

Spearman's correlation coefficients between carotid IMTs and coronary variables measured by QCA and IVUS are shown in Table 2 and Figure 1. Carotid-IMT_{mean} and Carotid-IMT_{max} showed a weak but significant correlation with the QCA-measured coronary-%DS_{max} or Gensini's score, with correlation coefficients ranging from 0.26 to 0.35. When IVUS coronary volumetric variables were considered, the correlation coefficients increased for PAV but not for TAV. Finally, when the two IVUS-determined IMT variables (Coronary-IMT_{mean} and Coronary-IMT_{max}) were compared with mean and max Carotid-IMT, the correlation coefficients increased further. Among the three selected carotid sites (common, bifurcation, and internal), carotid bifurcation showed the highest correlation with both QCA and IVUS parameters (Table 2). Table 2 also shows the same relationship investigated after data adjustment for age. In this partial correlation analysis, correlations between carotid and coronary IMTs variables and between PAV and Carotid-IMT_{max} or Bif-IMT_{mean} were still statistically significant.

Receiver operating characteristic curve analysis

The ability of ECU and QCA variables to classify patients with IVUS-documented coronary atherosclerosis correctly was tested by a receiver operating curve analysis and by logistic analyses. For this purpose, the whole group was divided into three subgroups according to their QCA results (Figure 2). Group A included patients with a QCA diagnosis of normality (coronary-%DS_{max} \leq 40%; *n* = 16); Group B, patients with a QCA diagnosis of intermediate coronary atherosclerosis (coronary-%DS_{max} > 40% and \leq 70%; *n* = 19); and Group C, patients with a diagnosis of overt coronary atherosclerosis (coronary-%DS_{max} > 70%; *n* = 13). Individual Coronary-IMT_{max} values of Group C were used to identify the most appropriate value of IVUS-detected Coronary-IMT to be used to classify patients included in Groups A and B as IVUS positive [IVUS⁽⁺⁾] or IVUS negative [IVUS^(–)] (Figure 2). Groups A and B patients were considered IVUS⁽⁺⁾ when their Coronary-IMT_{max} values exceeded the lowest Coronary-IMT_{max} value (0.608 mm) detected in the Coronary-IMT_{max} distribution of patients with a QCA diagnosis of overt atherosclerosis (Group C). Interestingly, this threshold value for the presence of coronary atherosclerosis fully agree with that reported by Tuzcu *et al.*³⁷ in patients of comparable range of age.

In Group A, 11 (68.8%) patients had a Coronary-IMT_{max} value <0.608 mm and five (31.2%) had a Coronary-IMT_{max} >0.608. Among Group B patients, three (15.8%) had a Coronary-IMT_{max} < 0.608 mm and 16 (84.2%) \geq 0.608 mm.

The ROC plots were obtained to evaluate the relative performance of ECU and QCA variables as tests for the presence of IVUS⁽⁺⁾ in patients of Groups A and B pooled together (Figure 3). The area under the ROC curve progressively increased from 0.730 to 0.798 and to 0.885 when calculated on the basis of coronary-%DS_{max}, Carotid-IMT_{max}, and Carotid-IMT_{mean}, respectively.

Figure 4 shows the results obtained when Carotid-IMT_{mean} was considered. The epidemiological data currently

Table 2 Spearman's and partial (adjusted for age) correlation coefficients between carotid intima-media thickness variables and quantitative coronary angiography and intravascular ultrasound coronary variables

Coronary variable	ECU variables				
	Carotid-IMT _{max}	Carotid-IMT _{mean}	CC-IMT _{mean}	ICA-IMT _{mean}	BIF-IMT _{mean}
QCA variables					
Coronary-%DS					
Unadjusted	0.32*	0.31*	0.21	0.20	0.28*
Age adjusted	0.25	0.10	0.12	-0.01	0.15
Gensini's score					
Unadjusted	0.35*	0.26	0.18	0.10	0.33*
Age adjusted	0.23	0.05	0.07	-0.11	0.18
IVUS volumetric variables					
TAV					
Unadjusted	0.23	0.33*	0.25	0.27	0.31*
Age adjusted	0.03	0.09	0.15	0.07	0.05
PAV					
Unadjusted	0.42**	0.41**	0.18	0.30*	0.47***
Age adjusted	0.34*	0.25	0.08	0.15	0.36*
IVUS IMT variables					
Coronary-IMT _{mean}					
Unadjusted	0.49**	0.52**	0.36*	0.39**	0.49**
Age adjusted	0.40**	0.40**	0.29*	0.28	0.41**
Coronary-IMT _{max}					
Unadjusted	0.52***	0.55***	0.40**	0.39**	0.53***
Age adjusted	0.41**	0.39**	0.28	0.25	0.44**

Partial correlation were performed after log (Gensini's score, TAV, Coronary IMTs, and carotid IMTs) or arcsin (Coronary-%DS and PAV) transformation.

* $P < 0.05$.

** $P < 0.01$.

*** $P < 0.0001$.

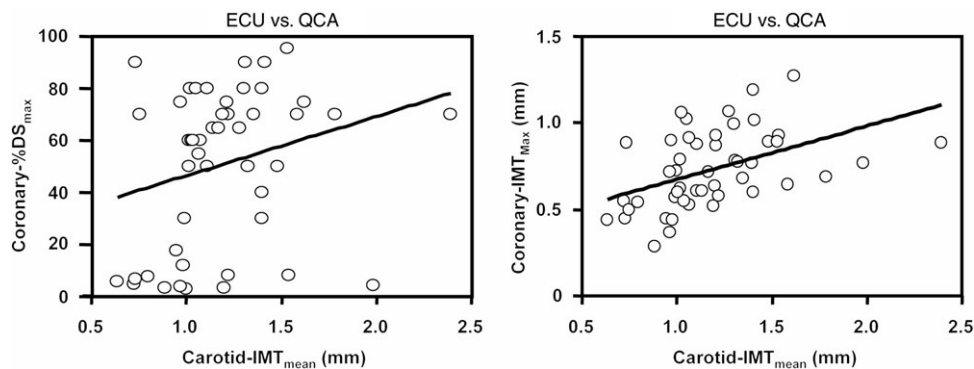


Figure 1 Linear regression plot comparing mean carotid intima-media thickness measured by external carotid ultrasound with coronary per cent diameter stenosis measured by quantitative coronary angiography (left panel, $r = 0.31$, $P = 0.03$) and maximal coronary intima-media thickness measured by intravascular ultrasound (right panel; $r = 0.55$, $P < 0.0001$).

available indicate that a Carotid-IMT_{mean} above 1 mm is associated with a significantly increased risk of myocardial infarction or cerebrovascular disease.^{7,9,38,39} Using this criterion, we identified no false negatives in either Group A or Group B; two out of 16 patients in Group A and two out of 19 patients in Group B were classifiable as false positives. Sensitivity, specificity, positive predictive value, and negative predictive value were 1, 0.75, 1, and 0.57 for Group A and 1, 0.25, 1, and 0.83 for Group B. The same parameters calculated for Groups A and B pooled together were 1, 0.63, 1, and 0.76.

The ROC analysis performed in Group C (patients with a QCA diagnosis of overt atherosclerosis) showed that the area under the ROC curve progressively decreased from

0.668 when calculated on the basis of QCA indexes of residual coronary lumen, to 0.628 with Carotid-IMT_{max} and to 0.602 with Carotid-IMT_{mean}.

In a logistic regression analysis performed in Groups A and B pooled together, the presence of a Carotid-IMT_{mean} > 1 mm was associated with an 18-fold increased risk of having a Coronary-IMT_{max} > 0.608 (OR = 17.99, 95% CI 1.83–177.14, $P = 0.013$). The presence of a Carotid-IMT_{mean} > 1 mm was also associated with a seven-fold increase of risk of having a haemodynamically significant (minimal lumen area < 4 mm²)⁴⁰ IVUS coronary stenosis (OR = 7.4, 95% CI 1.27–44.0, $P = 0.028$). Sensitivity, specificity, positive and negative predictive values, and test accuracy were 64, 75, 78, 60, and 75%, respectively.

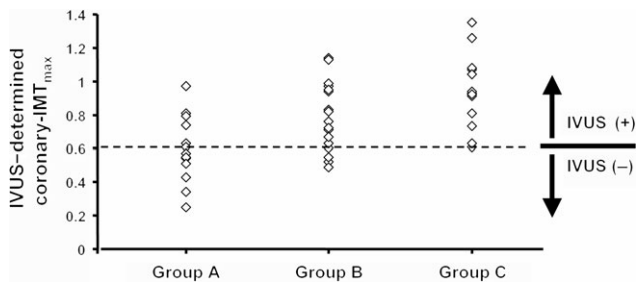


Figure 2 Coronary- IMT_{max} values in patients with a quantitative coronary angiography diagnosis of normality (coronary-%DS $\leq 40\%$, $n = 16$; Group A), intermediate coronary atherosclerosis (coronary-%DS $> 40\%$ and $\leq 70\%$, $n = 19$; Group B), and overt coronary atherosclerosis (coronary-%DS $> 70\%$, $n = 13$; Group C). Patients in Groups A and B were considered IVUS⁽⁺⁾ when their Coronary- IMT_{max} exceeded the lowest value (0.608 mm) observed in Group C.

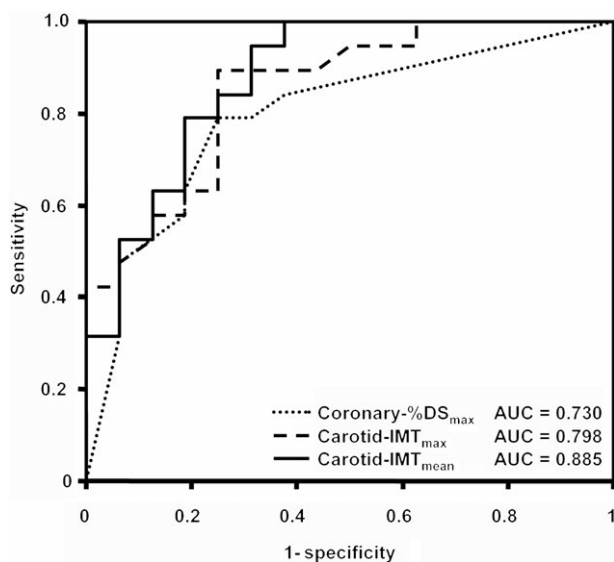


Figure 3 Receiver operating characteristic curves produced to evaluate the performance of quantitative coronary angiography and external carotid ultrasound variables to recognize patients with a positive IVUS test despite the presence of a quantitative coronary angiography diagnosis of intermediate coronary atherosclerosis or even of coronary normality. AUC, area under the receiver operating characteristic curve.

Discussion

Although extensively investigated,^{2,41–46} the value of carotid IMT as surrogate marker of coronary atherosclerosis is still a matter of debate. Studies showing significant higher carotid IMT values in patients with at least one coronary stenosis $\geq 50\%$ by QCA than in those without CAD,^{2,45} and postmortem studies documenting a high correlation between carotid and coronary atherosclerosis ($r \approx 0.55$)^{21–23,47} support the role of carotid IMT as a biomarker of atherosclerosis. However, other studies show that the correlation between carotid IMT and the severity of CAD as assessed by coronary angiography is relatively weak ($r = \sim 0.36$).^{14,20}

We have shown here that carotid IMT correlates much better with coronary atherosclerosis when both vascular beds are investigated by the same technique (ultrasound) and using the same parameter (IMT). In fact, when carotid IMT was correlated with IVUS-derived coronary-IMT, the correlation coefficients were higher than that with %DS by QCA,

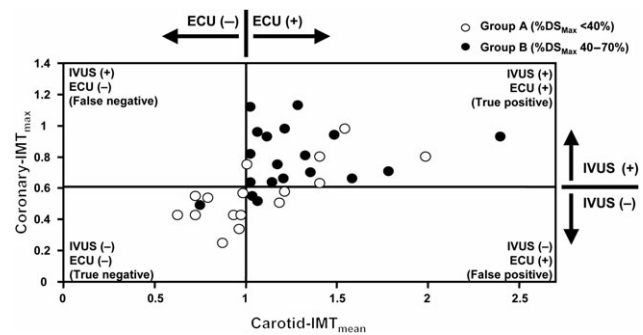


Figure 4 Scatter plot showing that patients with Carotid- $IMT_{mean} \geq 1$ mm have a high probability to be IVUS⁽⁺⁾, despite the presence of a quantitative coronary angiography diagnosis of intermediate coronary atherosclerosis or even of coronary normality.

and closer to those observed in pathology studies^{21–23,47} (Figure 5).

Since age might be the common denominator of such correlation, the analyses were repeated also after data adjustment for age. Even if a reduction in correlation coefficients was observed for all variables considered, almost all correlations between carotid and coronary IMTs maintained their statistical significance, whereas others, with the exception of the correlations between PAV and Carotid- IMT_{max} and Bif- IMT_{mean} , were no longer statistically significant.

This finding emphasizes the importance of using a method that precisely addresses vessel wall anatomy in both circulations and allows us to speculate that the weak correlation observed in ECU vs. QCA studies is probably due to the intrinsic inability of coronary angiography to measure the atherosclerotic burden precisely. In fact, the two-dimensional silhouette of contrast-filled lumen provides information mainly restricted to lumen diameter and no information about the real size of plaques. In addition, because there is no normal reference segment for comparison, the coronary artery of a patient with a diffuse concentric disease may appear to be nearly normal despite a huge atherosclerotic burden. In such cases, any correlation between carotid IMT and angiographic findings would be weak.

By providing a cross-sectional, real-time, tomographic perspective with direct visualization of the vessel wall, IVUS has the potential to overcome the limitations of angiography. However, in the only study published to date addressing the relationship between IVUS-detected coronary atherosclerosis and carotid ultrasonic results, the correlation coefficients obtained ($r \sim 0.40$), although slightly higher than that observed in QCA studies, were still lower than those observed in postmortem studies. Again in this case, homogeneous parameters were not used: the average maximum common carotid IMT measured by ECU was correlated with per cent coronary plaque area estimated by IVUS and not with coronary IMT.²⁹ In our study, carotid IMT variables correlated better with IVUS serial volumetric variables (PAV and TAV) than with %DS by QCA but still lower than those observed in postmortem studies and with coronary IMT. This finding indicates the importance of homogeneity of variables (i.e. IMT vs. IMT) in establishing the degree of correlation between carotid and coronary

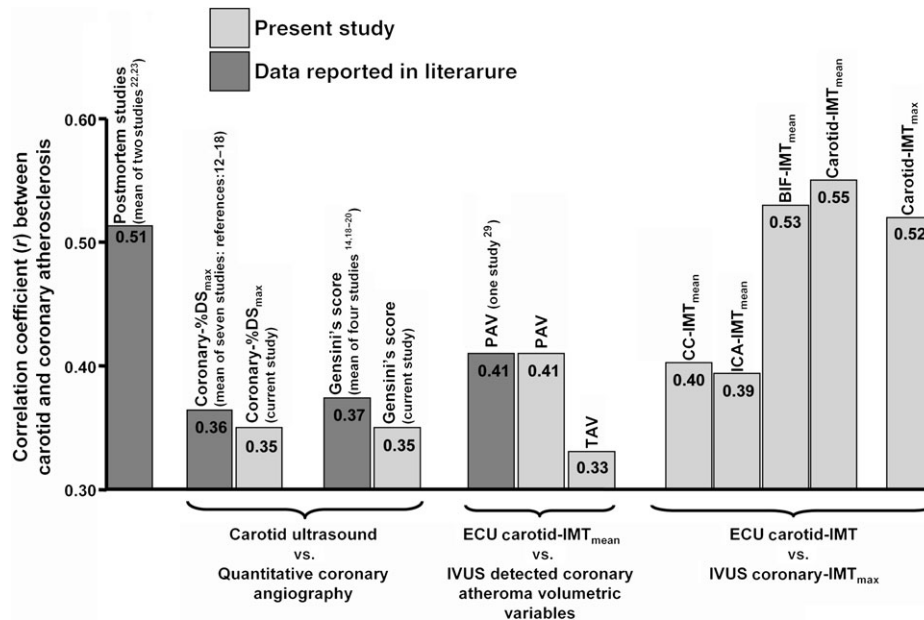


Figure 5 Comparison between correlation coefficients obtained in the present study (light histograms) vs. those obtained in postmortem, angiographic and intravascular ultrasound studies reported in the literature (dark grey histograms).

atherosclerosis, not merely that IVUS is more accurate than QCA in detecting coronary atherosclerosis.

What is the best site along the carotid tree as a marker of carotid or coronary atherosclerosis? Previous studies have shown that common carotid, bifurcation, and internal carotid have different relationships to atherosclerosis risk factors,⁴⁸ with plaques in common carotid developing later than in internal carotid arteries, carotid bifurcations, or coronary arteries.¹³ The development of atherosclerosis in carotid arteries generally starts with an increased IMT in the bifurcation area, probably due to the 'low shear stress' characteristic of this area, similar to what happens in coronary circulation.⁴⁹ We found Carotid-IMT_{max} and Carotid-IMT_{mean} (as aggregate measures obtained at the three carotid sites) to be the ECU variables most closely related to coronary IMT variables. Bifurcation was found to have the highest correlation with coronary IMT, with correlation coefficients similar to that obtained by using aggregate measurements (Table 2). Thus, if a single ultrasound measurement of the carotid is to be used, bifurcation should be the preferred site.

The fact that carotid and coronary IMT, both measured by ultrasound, correlate well does not provide conclusive evidence that carotid IMT is a surrogate index of coronary atherosclerosis. To further investigate this issue, we investigated the relative ability of ECU and QCA variables to recognize patients with a positive IVUS test [IVUS⁽⁺⁾] among those with a QCA diagnosis of no or intermediate coronary lesions.

Intermediate coronary lesions detected by QCA are a frequent occurrence in everyday cath lab practice. For example, Rensing *et al.*⁵⁰ found that among 1445 coronary stenoses evaluated by QCA in a CAD population, 80% were of intermediate degree. In these cases, additional tests to assess the significance of lumen narrowing may be required in order to treat or defer myocardial revascularization.

In our analysis, IVUS was considered the gold standard because of studies showing that (i) this technique is more

sensitive than angiography in detecting early atherosclerosis,^{27,51-53} (ii) it more accurately measures lumen diameter than angiography,⁵⁴ and (iii) it may be helpful in assessment and treatment guidance for angiographically indeterminate coronary artery disease.^{27,55-59} In addition, studies in patients with angiographically ambiguous CAD found an IVUS variable (the MLD) to be a good predictor of cardiac events.^{58,60}

In patients with normal/intermediate coronary atherosclerosis (Groups A and B pooled together) coronary-%DS_{max} showed the lowest power to discriminate IVUS⁽⁺⁾ from IVUS⁽⁻⁾ patients (area under the ROC curve = 0.730). The discriminating power increased by nearly 10% using Carotid-IMT_{max} and by about 20% using Carotid-IMT_{mean}. Interestingly, the presence of a Carotid-IMT_{mean} > 1 mm (or Carotid-IMT_{max} > 1.78 mm; data not shown) increases by 18 times the risk of having a Coronary-IMT_{max} > 0.608 (i.e. the lowest Coronary-IMT_{max} value observed in subjects with angiographic coronary stenosis) and indicates a positive IVUS test even in patients with a QCA diagnosis of coronary normality (empty circles in Figure 4). This latter observation confirms the close correlation between carotid and coronary IMTs but does not imply that carotid IMT is a predictor of the severity and extent of coronary atherosclerosis. Indeed, carotid and coronary IMT may be considered as markers of hypertrophy of intima and media layers of the artery wall, but they are not synonymous of atherosclerosis. To evaluate whether carotid IMT might predict the severity and extent of coronary atherosclerosis, we have investigated its ability to identify patients with a minimal lumen area < 4 mm² as detected by IVUS. This value was already selected by others⁴⁰ as a threshold to define a flow-limiting stenosis with a diagnostic accuracy of 92% in predicting a reduced coronary reserve (< 2.0) as evaluated by Doppler flow-wire. Interestingly, we found that patients with Carotid-IMT_{mean} > 1 mm had a seven-fold increase in the relative risk of having an IVUS-defined significant flow-limiting coronary stenosis,

with a positive predictive value of 78%. These findings suggest that at early stages of atherosclerosis disease, when mainly pre-intrusive coronary atherosclerotic lesions are present, ECU variables have a higher capacity than QCA variables to recognize patients with a positive IVUS test. In contrast, when the same analysis was performed in patients with a diagnosis of overt coronary atherosclerosis (Group C, coronary-%DS_{max} > 70%), the power to discriminate IVUS⁽⁺⁾ from IVUS⁽⁻⁾ patients was the highest with coronary-%DS_{max}, lower with Carotid-IMT_{max} (-6%), and lowest with Carotid IMT_{mean} (-10%), suggesting that in advanced atherosclerosis no additional tests to assess the significance of lumen narrowing is required.

Although obtained in a small sample, these results indicate the usefulness of carotid ultrasound as a further screening tool to identify patients who deserve consideration for a coronary IVUS test among those with a QCA diagnosis of intermediate lesions and even of coronary normality. It is important to note, however, that this study was performed in patients who had undergone cardiac catheterization because of suspected or proved heart diseases; thus, whether our results can be extended to patients without a cardiovascular history remains to be defined.

In addition, we must emphasize that we do not wish to suggest a coronary angiogram in all patients with carotid atherosclerosis, but rather that, in patients already selected for coronary angiography for symptoms or signs of ischemia and with coronary lesions by QCA <70%, the presence of a mean carotid IMT above 1 mm (or max carotid IMT above 1.78 mm) is a good indication for an IVUS investigation.

In conclusion, we found that carotid IMT correlates with coronary IMT much better than previously believed, which supports the concept that this variable is a good surrogate marker of coronary atherosclerosis. A Carotid-IMT_{mean} > 1 mm has also the potential to be a reliable indicator of a positive IVUS test in patients with angiographically normal/intermediate degree of arterial narrowing. Further studies involving a larger number of patients are required to confirm these observations.

Acknowledgements

Research described in this article was supported by Italian Ministry of Health (Ricerca Corrente).

Conflict of interest: none declared.

References

- Pignoli P, Tremoli E, Poli A, Oreste P, Paoletti R. Intimal plus medial thickness of the arterial wall: a direct measurement with ultrasound imaging. *Circulation* 1986;**74**:1399-1406.
- Craven TE, Ryu JE, Espeland MA, Kahl FR, McKinney WM, Toole JF, McMahan MR, Thompson CJ, Heiss G, Crouse JR. Evaluation of the associations between carotid artery atherosclerosis and coronary artery stenosis: a case-control study. *Circulation* 1990;**82**:1230-1242.
- Wendelhag I, Wiklund O, Wikstrand J. Atherosclerotic changes in the femoral and carotid arteries in familial hypercholesterolemia. Ultrasonographic assessment of intima-media thickness and plaque occurrence. *Arterioscler Thromb* 1993;**13**:1404-1411.
- O'Leary DH, Polak JF, Kronmal RA, Manolio TA, Burke GL, Wolfson SK Jr. Carotid-artery intima media thickness as a risk factor for myocardial infarction and stroke in older adults. *N Engl J Med* 1999;**340**:14-22.
- Heiss G, Sharrett AR, Barnes R, Chambless LE, Szklo M, Alzola C. Carotid atherosclerosis measured by B-mode ultrasound in populations:

associations with cardiovascular risk factors in the ARIC study. *Am J Epidemiol* 1991;**134**:250-256.

- O'Leary DH, Polak JF, Kronmal RA, Kittner SJ, Bond MG, Wolfson SK Jr, Bommer W, Price TR, Gardin JM, Savage PJ. Distribution and correlates of sonographically detected carotid artery disease in the Cardiovascular Health Study. The CHS Collaborative Research Group. *Stroke* 1992;**23**:1752-1760.
- Salonen JT, Salonen R. Ultrasonographically assessed carotid morphology and the risk of coronary heart disease. *Arterioscler Thromb* 1991;**11**:1245-1249.
- Geroulakos G, O'Gorman DJ, Kalodiki E, Sheridan DJ, Nicolaidis AN. The carotid intima-media thickness as a marker of the presence of severe symptomatic coronary artery disease. *Eur Heart J* 1994;**15**:781-785.
- Chambless LE, Heiss G, Folsom AR, Rosamond W, Szklo M, Sharrett AR, Clegg LX. Association of coronary heart disease incidence with carotid arterial wall thickness and major risk factors: the Atherosclerosis Risk in Communities (ARIC) Study, 1987-1993. *Am J Epidemiol* 1997;**146**:483-494.
- Van Der Meer IM, Bots ML, Hofman A, Iglesias Del Sol A, Van Der Kuip DA, Witteman JC. Predictive Value of Noninvasive Measures of Atherosclerosis for Incident Myocardial Infarction. The Rotterdam Study. *Circulation* 2004;**109**:1089-1094.
- de Groot E, Hovingh GK, Wiegman A, Duriez P, Smit AJ, Fruchart JC, Kastelein JJ. Measurement of arterial wall thickness as a surrogate marker for atherosclerosis. *Circulation* 2004;**109**:III33-III38.
- Herrington DM, Bean JA, Mercuri M. Strong correlation between carotid artery wall thickness and quantitative coronary angiographic assessment of coronary atherosclerosis. (Abstract). *Circulation* 1994;**90**:I-534.
- Blankenhorn DH, Hodis HN. Arterial imaging and atherosclerosis reversal. *Arterioscler Thromb* 1994;**14**:177-192.
- Adams MR, Nakagomi A, Keech A, Robinson J, McCredie R, Bailey BP, Feedman SB, Celermajer DS. Carotid intima-media thickness is only weakly correlated with the extent and severity of coronary artery disease. *Circulation* 1995;**92**:2127-2134.
- Holaj R, Spacil J, Petrasek J, Malik J, Aschermann M, Haas T. Relation of the thickness of the intima and media of the common carotid artery, atherosclerotic plaque in the carotids and manifestations of atherosclerosis in the vessels of the lower extremity in comparison to coronary atherosclerosis. *Cas Lek Cesk* 1998;**137**:716-720.
- Hulthe J, Wikstrand J, Emanuelsson H, Wiklund O, de Feyter PJ, Wendelhag I. Atherosclerotic Changes in the carotid artery bifurcation as measured by B-mode ultrasound are associated with the extent of coronary atherosclerosis. *Stroke* 1997;**28**:1189-1194.
- Balbarini A, Buttitta F, Limbruno U, Petronio AS, Baglini R, Strata G, Mariotti R, Ciccone M, Mariani M. Usefulness of carotid intima-media thickness measurement and peripheral B-mode ultrasound scan in the clinical screening of patients with coronary artery disease. *Angiology* 2000;**51**:269-279.
- Frick M, Schwarzacher SP, Alber HF, Rinner A, Ulmer H, Pachinger O, Weidinger F. Morphologic rather than functional or mechanical sonographic parameters of the brachial artery are related to angiographically evident coronary atherosclerosis. *J Am Coll Cardiol* 2002;**40**:1825-1830.
- Takashi W, Tsutomu F, Kentaro F. Ultrasonic correlates of common carotid atherosclerosis in patients with coronary artery disease. *Angiology* 2002;**53**:177-183.
- Holaj R, Spacil J, Petrasek J, Malik J, Haas T, Aschermann M. Intima-media thickness of the common carotid artery is the significant predictor of angiographically proven coronary artery disease. *Can J Cardiol* 2003;**19**:670-676.
- Mathur KS, Kashyap SK, Kumar V. Correlation of the extent and severity of atherosclerosis in the coronary and cerebral arteries. *Circulation* 1963;**27**:929-934.
- Holme I, Enger SC, Helgeland A, Hjermann I, Loren P, Lund-Larsen PG, Solberg LA, Strong JP. Risk factors and raised atherosclerotic lesions in coronary and cerebral arteries. *Arteriosclerosis* 1981;**1**:250-256.
- Young W, Gofman JW, Tandy R, Malmud N, Waters ESG. The quantitation of atherosclerosis, III: the extent of correlation of degrees of atherosclerosis within and between the coronary and cerebral vascular beds. *Am J Cardiol* 1960;**6**:300-308.
- Sternby NH. Atherosclerosis in a defined population. An autopsy survey in Malmo, Sweden. *Acta Pathol Microbiol Scand* 1968;**194**:5.
- Potkin BN, Bartorelli AL, Gessert JM, Neville RF, Almagor Y, Roberts WC, Leon MB. Coronary artery imaging with intravascular high-frequency ultrasound. *Circulation* 1990;**81**:1575-1585.
- Davidson CJ, Sheikh KH, Kisslo KB, Phillips HR, Peter RH, Behar VS, Kong YH, Krucoff M, Ohman EM, Tchong JE, Stack RS. Intracoronary

- ultrasound evaluation of interventional technologies. *Am J Cardiol* 1991; **68**:1305-1309.
27. Nissen SE, Gurley JC, Grines CL, Booth DC, McClure R, Berk M, Fischer C, DeMaria AN. Intravascular ultrasound assessment of lumen size and wall morphology in normal subjects and patients with coronary artery disease. *Circulation* 1991; **84**:1087-1099.
 28. Fitzgerald PJ, St Goar FG, Connolly AJ, Pinto FJ, Billingham ME, Popp RL, Yock PG. Intravascular ultrasound imaging of coronary arteries. Is three layers the norm? *Circulation* 1992; **86**:154-158.
 29. Ogata T, Yasaka M, Yamagishi M, Seguchi O, Nagatsuka K, Minematsu K. Atherosclerosis found on carotid ultrasonography is associated with atherosclerosis on coronary intravascular ultrasonography. *J Ultrasound Med* 2005; **24**:469-474.
 30. Touboul PJ, Prati P, Scarabin PY, Adrai V, Thibout E, Ducimetiere P. Use of monitoring software to improve the measurement of carotid wall thickness by B-mode imaging. *J Hypertens Suppl* 1992; **10**:S37-S41.
 31. Gensini GG. A more meaningful scoring system for determining the severity of the coronary heart disease. *Am J Cardiol* 1983; **51**:606.
 32. Fuesl RT, Mintz GS, Pichard AD, Kent KM, Satler LF, Popma JJ, Leon MB. *In vivo* validation of intravascular ultrasound length measurements using a motorized transducer pullback device. *Am J Cardiol* 1996; **77**:1115-1118.
 33. Mintz GS, Nissen SE, Anderson WD, Bailey SR, Erbel R, Fitzgerald PJ, Pinto FJ, Rosenfield K, Siegel RJ, Tuzcu EM, Yock PG. American College of Cardiology Clinical Expert Consensus Document on Standards for Acquisition, Measurement and Reporting of Intravascular Ultrasound Studies (IVUS). A report of the American College of Cardiology Task Force on Clinical Expert Consensus Documents. *J Am Coll Cardiol* 2001; **37**:1478-1492.
 34. Montorsi P, Galli S, Fabbiochi F, Loaldi A, Trabattini D, Grancini L, Cozzi S, Ravagnani P, Parodi O, Bartorelli AL. Mechanism of cutting balloon angioplasty for in-stent restenosis: an intravascular ultrasound study. *Catheter Cardiovasc Interv* 2002; **56**:166-173.
 35. Nissen SE, Tsunoda T, Tuzcu EM, Schoenhagen P, Cooper CJ, Yasin M, Eaton GM, Lauer MA, Sheldon WS, Grines CL, Halpern S, Crowe T, Blankenship JC, Kerensky R. Effect of recombinant apoA-I Milano on coronary atherosclerosis in patients with acute coronary syndromes: A randomized controlled trial. *JAMA* 2003; **290**:2292-2300.
 36. Bland JM, Altman DG. Statistical methods for assessing agreement between two methods of clinical measurement. *Lancet* 1986; **1**:307-310.
 37. Tuzcu EM, Kapadia SR, Tutar E, Ziada KM, Hobbs RE, McCarthy PM, Young JB, Nissen SE. High prevalence of coronary atherosclerosis in asymptomatic teenagers and young adults: evidence from intravascular ultrasound. *Circulation* 2001; **103**:2705-2710.
 38. Chambless LE, Folsom AR, Sharrett AR, Sorlie P, Couper D, Szklo M, Nieto FJ. Coronary heart disease risk prediction in the Atherosclerosis Risk in Communities (ARIC) study. *J Clin Epidemiol* 2003; **56**:880-890.
 39. Folsom AR, Chambless LE, Duncan BB, Gilbert AC, Pankow JS; Atherosclerosis Risk in Communities Study Investigators. Prediction of coronary heart disease in middle-aged adults with diabetes. *Diabetes Care* 2003; **26**:2777-2784.
 40. Abizaid A, Mintz GS, Pichard AD, Kent KM, Satler LF, Walsh CL, Popma JJ, Leon MB. Clinical, Intravascular Ultrasound, and Quantitative Angiographic Determinants of the Coronary Flow Reserve Before and After Percutaneous Transluminal Coronary Angioplasty. *Am J Cardiol* 1998; **82**:423-428.
 41. Howard G, Ryu JE, Evans GW, McKinney WM, Toole JF, Murros KE, Crouse JR III. Extracranial carotid atherosclerosis in patients with and without transient ischemic attacks and coronary artery disease. *Arteriosclerosis* 1990; **10**:714-719.
 42. Wofford JL, Kahl FR, Howard GR, McKinney WM, Toole JF, Crouse JR. Relation of extent of extracranial carotid artery atherosclerosis as measured by B-mode ultrasound to the extent of coronary atherosclerosis. *Arterioscler Thromb* 1991; **11**:1786-1794.
 43. Bruckert E, Giral P, Salloum J, Kahn JF, Dairou F, Truffert J, Reverdy V, Thomas D, Evans J, Grosgeat Y. Carotid stenosis is a powerful predictor of a positive exercise electrocardiogram in a large hyperlipidemic population. *Atherosclerosis* 1992; **92**:105-114.
 44. Geroulakos G, O'Gorman D, Nicolaides A, Sheridan D, Elkeles R, Shaper AG. Carotid intima-media thickness: correlation with the British regional heart study risk score. *J Intern Med* 1994; **235**:431-433.
 45. Crouse JR 3rd, Craven TE, Hagaman AP, Bond MG. Association of coronary disease with segment-specific intimal-media thickening of the extracranial carotid artery. *Circulation* 1995; **92**:1141-1147.
 46. Nagai Y, Metter EJ, Earley CJ, Kemper MK, Becker LC, Lakatta EG, Fleg JL. Increased carotid intimal-media thickness in asymptomatic older subjects with exercise-induced myocardial ischemia. *Circulation* 1998; **98**:1504-1509.
 47. Jashnani KD, Kulkarni RR, Deshpande JR. Role of carotid intima-media thickness in assessment of atherosclerosis: an autopsy study. *Indian Heart J* 2005; **57**:319-323.
 48. Ludwig MM, Jörger U, Lund S, Stumpe KO. Divergent responses of common carotid artery intimal-medial thickness to high blood pressure and hypercholesterolaemia in relation to age. *J Hypertens* 1993; **11**:130-131.
 49. Glagov S, Zarins C, Giddens DP, Ku DN. Hemodynamics and atherosclerosis: insights and perspectives gained from studies of human arteries. *Arch Pathol Lab Med* 1988; **112**:1018-1031.
 50. Rensing BJ, Hermans WR, Deckers JW, de Feyter PJ, Tijssen JG, Serruys PW. Lumen narrowing after percutaneous transluminal coronary balloon angioplasty follows a near gaussian distribution: a quantitative angiographic study in 1,445 successfully dilated lesions. *J Am Coll Cardiol* 1992; **19**:939-945.
 51. Nishimura RA, Edwards WD, Warnes CA, Reeder GS, Holmes DR Jr, Tajik AJ, Yock PG. Intravascular ultrasound imaging: *in vitro* validation and pathologic correlation. *J Am Coll Cardiol* 1990; **16**:145-154.
 52. St Goar FG, Pinto FJ, Alderman EL, Fitzgerald PJ, Stadius ML, Popp RL. Intravascular ultrasound imaging of angiographically normal coronary arteries: an *in vivo* comparison with quantitative angiography. *J Am Coll Cardiol* 1991; **18**:952-958.
 53. Porter TR, Sears T, Xie F, Michels A, Mata J, Welsh D, Shurmur S. Intravascular ultrasound study of angiographically mildly diseased coronary arteries. *J Am Coll Cardiol* 1993; **22**:1858-1865.
 54. Cooper BZ, Kirwin JD, Panetta TF, Weinreb FM, Ramirez JA, Najjar JG, Blattman SB, Rodino W, Song M. Accuracy of intravascular ultrasound for diameter measurement of phantom arteries. *J Surg Res* 2001; **100**:99-105.
 55. Nishimura RA, Higano ST, Holmes DR Jr. Use of intracoronary ultrasound imaging for assessing left main coronary artery disease. *Mayo Clin Proc* 1993; **68**:134-140.
 56. Pirolo JS, Fredi JL, Shuman TA. Intracoronary ultrasound-guided CABG in patients with angiographically noncritical lesions. *Cardiovascular Surgery Associates. Ann Thorac Surg* 1997; **64**:375-379.
 57. Russo RJ. Ultrasound-guided stent placement. *Cardiol Clin* 1997; **15**:49-61.
 58. Abizaid A, Pichard AD, Mintz GS, Abizaid AS, Klutstein MW, Satler LF, Mehran R, Leiboff B, Kent KM, Leon MB. Acute and long-term results of an intravascular ultrasound-guided percutaneous transluminal coronary angioplasty/provisional stent implantation strategy. *Am J Cardiol* 1999; **84**:1298-1303.
 59. Park SJ, Hong MK, Lee CW, Kim JJ, Song JK, Kang DH, Park SW, Mintz GS. Elective stenting of unprotected left main coronary artery stenosis: effect of debulking before stenting and intravascular ultrasound guidance. *J Am Coll Cardiol* 2001; **38**:1054-1060.
 60. Ricciardi MJ, Meyers S, Choi K, Pang JL, Goodreau L, Davidson CJ. Angiographically silent left main disease detected by intravascular ultrasound: a marker for future adverse cardiac events. *Am Heart J* 2003; **146**:507-512.